



**PATIENT**  
Ozzy Devito

**PRESENTING CLINICAL SIGNS**

History: Ozzy was noted to have a heart murmur in September. Adopted two months ago. Good appetite and active and playful. On exam: NSR, grade II/VI parasternal murmur, PSS, lung fields clear, compressible thorax, mm pink moist. BP: 140mmHg x 5. \*Sedated with propofol for study.

**SPECIES**  
Feline

**ECHOCARDIOGRAM FINDINGS**

2D, m-mode, color flow and Doppler imaging is available.

**BREED**  
DSH

**Left ventricle:** The LV diameter is borderline normal with adequate myocardial function. The LV wall thicknesses are normal. The papillary muscles are normal. The endocardium appears normal.

**SEX**

Male Intact

**Left atrium:** The left atrium is normal in dimension, although bulbous in appearance. No obvious spontaneous contrast or thrombi seen.

**Mitral valve:** The mitral valve is normal in structure and mobility. No obvious systolic anterior motion is seen. No MR.

**AGE**

17 weeks

**Aortic valve/Aorta:** The aortic valve is normal in morphology and mobility. Normal aortic outflow velocity; laminar flow. No aortic insufficiency.

**Right ventricle:** Normal right ventricular diameter and morphology indicating no overt evidence of pulmonary arterial hypertension.

**Right atrium:** The right atrium is normal in dimension.

**WEIGHT**

4.5lbs

**Tricuspid valve:** The tricuspid valve appears normal with trace tricuspid regurgitation.

**Pulmonic valve/Pulmonary artery:** The pulmonic valve is normal in morphology and mobility. No pulmonic insufficiency. Normal RVOT velocity; laminar flow.

**Pericardium/other:** No obvious congenital shunts. No pericardial or pleural effusion noted. No obvious cardiac masses.

**INTERPRETED BY**

Maggie Machen  
Lamy, DVM  
DACVIM (Cardiology)

**Heart rhythm:** ECG reveals a sinus rhythm with an average HR of 160bpm.

**2-Dimensional Measurements**

Ao diam (cm)	0.7
LA diam (cm)	1.0
LA:Ao (Swe)	1.4
IVS thickness (cm)	0.39
LVID diastole (cm)	1.5
PW thickness (cm)	0.41
LVID systole (cm)	0.64
FS (%)	54

**Doppler Measurements**

PV Vmax (m/s)	0.8
AoV Vmax (m/s)	1.2
MR Vmax (m/s)	NA
TR Vmax (m/s)	NA
TR PG (mmHg)	NA

**IMAGING PERFORMED BY**

Pamela Harrigan,  
RDCS

**HOSPITAL NAME**

Mass Veterinary Services

**REFERRING VET**

Dr. Masloski

**INVOICE**

27225

**DATE**

11/1/22

**INTERPRETATION OF THE FINDINGS**

Overtly normal cardiac structure and function. The LV wall thickness is normal and there is no evidence of elevated left atrial pressure. Of some concern, the LA and LV appear borderline for this body size and follow up is advised to ensure no progressive issues are identified. No obvious congenital defects are seen at this time. No cause for the murmur is identified in this study, making it likely physiologic in origin (i.e., secondary to tachycardia, volume changes, etc.).



**PATIENT**

Ozzy Devito

**SPECIES**

Feline

**BREED**

DSH

**SEX**

Male Intact

**AGE**

17 weeks

**WEIGHT**

4.5lbs

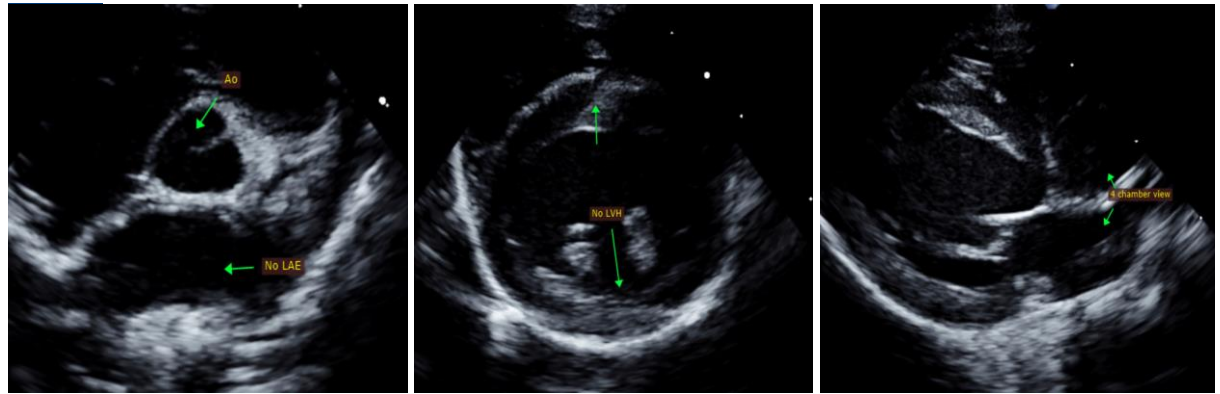
**RECOMMENDATIONS**

- Given these findings, no medications are indicated.
- No cardiac contraindication for general anesthesia.
- Monitor for any clinical evidence of cardiac compromise, including respiratory changes and/or signs of a blood clot event (paralysis, neurologic changes, etc.).

**PLAN**

- Recommend recheck echocardiogram in 1 year to reassess murmur origin and screen for development of disease the pre-existing murmur may mask.

**IMAGES**



**INTERPRETED BY**

Maggie Machen Lamy, DVM  
DACVIM (Cardiology)

The information and recommendations provided are based on the images presented by the referring veterinarian. No evaluation can be communicated regarding pathology that was not visible in the image/video clips provided.

Thank you for this referral. This report was generated using transcription software, and minor dictation errors may be present. If the clinical or image interpretation does not parallel your findings or if I can be of any further assistance, please contact me.

**IMAGING PERFORMED BY**

Pamela Harrigan, RDCS

Maggie Machen Lamy, DVM  
Diplomate of the American College of Veterinary Internal Medicine (Cardiology)  
info@sonopath.com

**HOSPITAL NAME**

Mass Veterinary Services

Echocardiogram performed by:

Pamela Harrigan, RDCS  
Pet Animal Ultrasound Service (4paus.com)

**REFERRING VET**

Dr. Masloski

**INVOICE**

27225

**DATE**

11/1/22